FILED
Court of Appeals
Division II
State of Washington
1/26/2018 2:27 PM

No. 50336-1-II

THE COURT OF APPEALS FOR THE STATE OF WASHINGTON
DIVISION II

GERALDINE IVERSON,
as personal representative of BESSIE RITTER,

Appellant,

v.

PRESTIGE CARE, INC.
and NORTHWEST COUNTRY PLACE, INC.,

Respondents.

Appeal from the Superior Court of Washington for Lewis County

---

BRIEF OF RESPONDENTS

Matthew J. Kalmanson
WSBA No. 41262
Hart Wagner LLP
1000 SW Broadway
Twentieth Floor
Portland, OR 97205
mjk@hartwagner.com

TABLE OF CONTENTS

I. INTRODUCTION 1

II. RESTATEMENT OF ISSUES PERTAINING TO APPELLANTS' ASSIGNMENTS OF ERROR 1

1. Whether the trial court properly granted summary judgment because plaintiff failed to establish that her expert's opinion on causation was based on a generally accepted scientific theory. 1

2. Whether the trial court properly denied a motion for reconsideration on the same grounds. 1

III. STATEMENT OF THE CASE 2

IV. ARGUMENT 4

a. Expert testimony under *Frye*. 5

b. Plaintiff misconstrues *Anderson*. 8

c. Plaintiff failed to submit evidence that her expert's theory is generally accepted. 12

i. Plaintiff cannot support the underlying scientific theory at issue by relying solely on Dr. Brentnall's opinion. 12

ii. Plaintiff's proffered scientific literature does not support the underlying scientific theory at issue. 14

iii. Because Dr. Brentnall's scientific theory is unsupported, her differential diagnosis cannot support her opinion. 17

V. CONCLUSION 19

APPENDIX

"Management of the Colonic Volvulus in 2016" A-1

"Colonic Atony in Association with Sigmoid Volvulus: It's Role in Recurrence of Obstructive Symptoms" A-11

TABLE OF AUTHORITIES

Cases

Anderson v. Akzo Nobel Coatings, Inc.,
172 Wn.2d 593, 260 P.3d 857 (2011).....*passim*

Frye v. United States,
293 F 1013 (D.C. Cir. 1923).....*passim*

Lake Chelan Shores Homeowners Ass'n v. St. Paul Fire & Marine Ins. Co.,
176 Wn. App. 168, 313 P.3d 408 (2013).....10, 11, 12, 13

Reese v. Stroh,
128 Wn.2d 300, 907 P.2d 282 (1995).....5

Ruff v. Dept. of Labor & Indus.,
107 Wn. App 289, 28 P.3d 1 (2001).....12

State v. Copeland,
130 Wn.2d 244, 922 P.2d 1304 (1996).....6, 12

State v. Gore,
143 Wn.2d 288, 21 P.3d 262 (2001).....7

State v. Gregory,
158 Wn.2d 759, 147 P.3d 1201 (2006).....7

Rules

ER 702 .....5, 7

I. INTRODUCTION

Plaintiff, the personal representative of the Estate of Bessie Ritter, sued defendants Prestige Care and Northwest Country Place, Inc. for negligence and violation of Washington's Vulnerable Adults Act ("VAA"). Both claims concern defendants' alleged failure to treat Ms. Ritter's constipation, which plaintiff argues caused a cecal volvulus to develop, resulting in Ms. Ritter's death. Defendants filed a motion for summary judgment, arguing that plaintiff's expert testimony on causation was inadmissible under the *Frye* test. The trial court agreed and granted summary judgment. Plaintiff now appeals the trial court's order granting summary judgment.

II. RESTATEMENT OF ISSUES PERTAINING TO APPELLANTS' ASSIGNMENTS OF ERROR

1. Whether the trial court properly granted summary judgment because plaintiff failed to establish that her expert's opinion on causation was based on a generally accepted scientific theory.

2. Whether the trial court properly denied a motion for reconsideration on the same grounds.

III. STATEMENT OF THE CASE

On July 25, 2014, Ms. Ritter was admitted to Liberty Country Place ("NCPI"), a nursing home in Centralia, Washington. CP 1-2, 8. Part of Ms. Ritter's care plan included the house bowel protocol. CP 504, 506-507. On August 30, 2014, Nurse Harmony Spencer gave Ms. Ritter Milk of Magnesia, per the house bowel protocol. CP 379. The next day, on August 31, 2014, Ms. Ritter still had not had a bowel movement, so Nurse Garrett administered a Dulcolax suppository. CP 389. By the following evening, September 1, 2014, Ms. Ritter had vomited more than once and a nurse noted that her abdomen was firm and tender. That night, the nurse sent Ms. Ritter to the hospital. CP 390, 392.

After arriving at Providence Centralia Hospital Emergency Department, Ms. Ritter underwent imaging studies and a doctor diagnosed a small bowel obstruction and acute renal failure. CP 395-403. A different doctor consulted on Ms. Ritter's treatment later that night and diagnosed her with abdominal pain secondary to bowel obstruction of unclear etiology, likely from adhesions. CP 409.

Ms. Ritter underwent surgery but she ultimately died a few days following the surgery. CP 2, 424-27. A pathology report on September 5, 2014 diagnosed Ms. Ritter with, among other things, serosal adhesions. CP 340-41.

Plaintiff then filed this lawsuit, alleging that the NCPI staff failed to monitor Ms. Ritter's bowel movements, failed to act on her lack of bowel movements and failed to answer her call light. CP 2. Plaintiff claims that those alleged failures caused Ms. Ritter's death. *Id.* Specifically, plaintiff argued that defendants' negligence caused Ms. Ritter to develop a cecal volvulus, resulting in the rupture of her colon and, ultimately, her death.[1] CP 1-3; 484-86.

In support of this theory, plaintiff relied on the testimony of three expert witnesses. This appeal, however, concerns only one of plaintiff's experts, Teresa Brentnall, M.D. ("Dr. Brentnall"). CP 481-487. Dr. Brentnall was the only of plaintiff's experts to testify regarding causation. RP 18:11-18.

Defendants filed a motion for summary judgment arguing, *inter alia*, that the underlying scientific theory supporting Dr.

---

[1] A cecal volvulus is a twisting of the colon.

Brentnall's opinion on causation was not generally accepted in the scientific community under the "*Frye* test." CP 336-354; 622-634. The trial court agreed and entered an order of summary judgment in favor of defendants. CP 764-65; RP 22:1-4.

Plaintiff now appeals that order, arguing that the trial court improperly applied *Frye*'s standard for evaluating the admissibility of expert testimony to Dr. Brentnall's opinion on causation.

IV. ARGUMENT

Plaintiff's primary contention on appeal is that the trial court improperly applied the *Frye* test for admitting expert testimony on causation. Plaintiff argues that *Anderson v. Akzo Nobel Coatings, Inc.*, 172 Wn.2d 593, 260 P.3d 857 (2011), forecloses application of *Frye* to Dr. Brentnall's opinion.

Plaintiff misconstrues both *Anderson* and the trial court's ruling. The trial court granted summary judgment because plaintiff failed to identify a single piece of medical literature that supports the scientific theory that constipation causes a cecal volvulus. As this scientific theory – that constipation causes a cecal volvulus – was included in the differential diagnosis that plaintiff's expert used to

conclude that defendants caused Ms. Ritter's death, the trial court properly excluded this opinion and granted summary judgment.

This court reviews *de novo* the trial court's application of the *Frye* standard. *Anderson*, 172 Wn.2d at 600. Summary judgments are also reviewed *de novo*, "with all inferences taken in favor of the nonmoving party." *Id.*

a. Expert testimony under *Frye*.

Expert testimony is required to prove causation when knowledge beyond that of an ordinary layperson is needed to understand the issue. *Reese v. Stroh*, 128 Wn.2d 300, 308, 907 P.2d 282 (1995). Accordingly, when a plaintiff fails to produce admissible testimony from a qualified medical expert that defendant caused the alleged injuries, the trial court must grant summary judgment in defendant's favor. *Id.*

The admissibility of expert testimony is governed by ER 702, which allows for the admission of expert testimony that will aid the jury in understanding matters requiring more than lay knowledge. *Anderson*, 172 Wn.2d at 600–01. If an expert's opinion is based on novel scientific evidence, however, then it must satisfy the threshold

standard announced in *Frye v. United States*, 293 F 1013 (D.C. Cir. 1923). *See State v. Copeland*, 130 Wn.2d 244, 259, 922 P.2d 1304 (1996) (so stating).

The *Frye* standard restricts the admission of expert testimony to opinions that are based on theories or principles that are generally accepted in the relevant scientific community. *Id.* at 261. Because judges and juries lack the expertise required to determine whether a challenged scientific theory is reliable, the *Frye* standard requires courts to defer to scientists in the relevant scientific community. *Id.* at 259. The *Frye* standard is a critical threshold test designed to filter out expert testimony that is based on unreliable scientific theories or methodologies. *Id.* at 255.

Frye requires a party to show two things before a qualified expert may testify to causation: (1) proof of reliance on a generally accepted scientific theory and (2) proof of the use of a generally accepted methodology to implement that scientific theory. *Id.* If these threshold steps are satisfied, then the expert testimony is admissible, assuming there are no other reasons to exclude the testimony.

The Washington Supreme Court recently explained in *Anderson* how *Frye* applies when causation is at issue, stating:

> The primary goal is to determine 'whether the evidence offered is based on established scientific methodology.' *State v. Gore*, 143 Wn.2d 288, 302, 21 P.3d 262 (2001). Both the scientific theory underlying the evidence and the technique or methodology used to implement it must be generally accepted in the scientific community for evidence to be admissible under *Frye*.

172 Wn.2d at 603 (quoting *State v. Gregory*, 158 Wn.2d 759, 829, 147 P.3d 1201 (2006)).

If a party proves that the underlying scientific theory and methodology is generally accepted in the scientific community, then the expert's ultimate opinion as to causation – *i.e.* the "application of the science to a particular case" – is simply "a matter of weight and admissibility under ER 702." *Id.* In other words, while the *Frye* standard does not directly apply to an expert's ultimate opinion as to <u>whether</u> a defendant's conduct caused an injury, the scientific theory and methodology that underlies that opinion must be generally accepted in the scientific community. If it is not, then the expert testimony is inadmissible.

b. Plaintiff misconstrues *Anderson*.

Before applying *Frye* to the facts in this case, it is important to note that plaintiff misconstrues *Anderson*, defendants' summary judgment motion, and the trial court's ruling. Plaintiff argues repeatedly on appeal that defendants led the trial court into error by asking it to apply *Frye* to Dr. Brentnall's ultimate opinion on causation, which is contrary to *Anderson.* This is the same misguided argument that plaintiff made below. Defendants did not then, and do not now, argue that *Frye* applies to Dr. Brentnall's ultimate opinion on causation. Nor did the trial court grant summary judgment on that basis.

Rather, the trial court granted summary judgment because plaintiff failed to prove that the scientific theory underlying Dr. Brentnall's opinion – that constipation causes a cecal volvulus – is generally accepted in the scientific community. In stark contrast to plaintiff's framing of the trial court's ruling, the trial court explained:

> "So there was some discussion, an expert's ultimate opinion, as to what caused the damage in this particular case. That doesn't have to be generally accepted. The opinions can be varied as long as it's based on something that is a methodology that is generally accepted, and we don't have here."

RP 20:18-23.

The trial court then observed that evidence supporting the theory that constipation causes a cecal volvulus "is just missing." Therefore, the "only conclusion [the trial court] can reach is that because it is not there it is not generally accepted in the scientific community, in the medical community." RP 21:11-17. That is, while Dr. Brentnall used an accepted methodology to develop her ultimate conclusion on causation (a differential diagnosis), she erred in the application of that methodology because it included a flawed scientific theory that constipation causes a cecal volvulus.

Both below and on appeal plaintiff conflates different concepts. *Frye* applies to a determination that something <u>can</u> cause a result, not an expert's opinion as to whether something <u>did</u> cause a result. Plaintiff asks this court to hold that *Frye* does not apply even to the threshold question of whether something <u>can</u> cause a result, if that question goes to causation. That is not what *Anderson* holds.

This court, in fact, already considered and rejected an almost identical argument in *Lake Chelan Shores Homeowners Ass'n v. St. Paul Fire & Marine Ins. Co.*, 176 Wn. App. 168, 313 P.3d 408 (2013). There, the plaintiff sought to prove that "collapse" conditions occurred during a policy period. *Id.* at 172. To that end, plaintiff relied on experts who opined that the buildings were in "collapse" during the policy period, ten years before the discovery of the problem. *Id.* at 174.

The defendant moved for partial summary judgment on the ground that that the expert testimony was inadmissible under *Frye*. *Id.* at 175. Specifically, the defendant argued that plaintiff's experts "had no generally accepted scientific basis on which to link the current building decay to a state of 'collapse' during the [defendant's] policy periods." *Id.* at 174. The trial court agreed and dismissed the plaintiff's collapse coverage claims. *Id.*

On appeal, like plaintiff in this case, the plaintiff relied on *Anderson* in arguing that "the trial court below, like the trial court in [*Anderson*], improperly required general acceptance of its experts' conclusions." *Id.* at 180. The appellate court disagreed, stating that *Anderson* does not help the plaintiff because "the issue here is not the

scientific community's general acceptance of [the expert's] conclusions regarding the onset of the state of collapse, but instead whether the methodology by which those conclusions were reached is generally accepted." *Id.* at 181. The court observed that "[defendant] pointed to an absence of evidence that the bases of the opinions offered by [plaintiff's] experts were generally accepted and [plaintiff] failed to respond." *Id.* at 179. Accordingly, "the trial court did not err in concluding that the opinions were inadmissible and that [plaintiff] could not prove a collapse condition existed during the coverage period." *Id.*

Plaintiff's argument closely parallels the plaintiff's unsuccessful argument in *Lake Chalen Shores*. Plaintiff incorrectly frames the trial court's holding as improperly applying *Frye* to the expert's ultimate opinion on causation. The court rejected that argument in *Lake Chalen Shores*, explaining that there is a difference between the ultimate issue of causation and the scientific theory and methodology by which that conclusion was reached. *Id.* at 181.

c. Plaintiff failed to submit evidence that her expert's theory is generally accepted.

Plaintiff's expert testimony fails the first prong of *Frye* because it is not based on a generally accepted scientific theory. To allow Dr. Brentnall to testify that she used a differential diagnosis to conclude that Ms. Ritter's constipation caused her cecal volvulus, it must be generally accepted that constipation can cause a cecal volvulus.

In determining whether *Frye* is satisfied, courts consider "the available scientific literature, secondary legal authority, and cases in other jurisdictions." *Ruff v. Dept. of Labor & Indus.*, 107 Wn. App 289, 28 P.3d 1 (2001) (citing *Copeland*, 130 Wn.2d at 255-256). "Scientific opinion need not be unanimous," but "if there is significant dispute between qualified experts as to the validity of the scientific evidence, it may not be admitted." *Copeland*, 130 Wn.2d at 255.

i. Plaintiff cannot support the underlying scientific theory at issue by relying solely on Dr. Brentnall's opinion.

In opposition to defendants' motion for summary judgment, plaintiff argued that Dr. Brentnall's opinion was admissible because it was based on "the medical facts in this case contained in the records, by her experience, and by literature that shows the impact of a large

stool burden on the body." CP 475. Plaintiff's first two pieces of support (the medical records and her experience) are irrelevant under *Frye*.

Under *Frye*, the party seeking to admit expert testimony must prove that the underlying scientific theory is generally accepted in the scientific community. Accordingly, a party cannot support the general acceptance of a scientific theory by pointing only to the medical records or their expert's experience. *See Lake Chelan* Shores, 176 Wn. App. at 181 (stating that an expert witness's knowledge and experience are not relevant under the *Frye* analysis).

For example, in her Opening Brief, plaintiff attempts to support the underlying scientific theory by citing a quote from Dr. Brentnall that, in her opinion, "Patients with constipation are 7 times more likely to develop volvulus." CP 485. This is precisely the kind of opinion evidence that is inadmissible unless it is backed up by medical literature showing that it is generally accepted in the scientific community.

ii. Plaintiff's proffered scientific literature does not support the underlying scientific theory at issue.

The court granted summary judgment because plaintiff failed to submit scientific literature or other evidence that supports Dr. Brentnall's opinion. The literature plaintiff submitted shows that there are two main types of constipation, acute or chronic. The two types of constipation are differentiated on a temporal basis – acute constipation is constipation for less than nine days and chronic constipation is constipation that is longer than nine days. CP 348.

In the trial court, there was a factual dispute as to the precise gap between Ms. Ritter's bowel movements. This dispute might have been significant because Dr. Brentnall testified that it was chronic constipation that caused a cecal volvulus. CP 348-49, 481-487. However, because the two scientific articles that plaintiff provided to the court on causation did not support Dr. Brentnall's theory that chronic constipation causes a cecal volvulus, that factual issue is irrelevant to the issues on appeal.[2] The trial court expressly noted this:

---

[2] Those articles are attached to the appendix of this brief.

> I agree there are issues about whether there was a bowel movement or not. That is a factual issue. There is enough information here that I can't decide that. But that's not determinative of the ultimate question here because that really comes down to the question of causation and that's what the bottom line is.

RP 18: 4-10. That is, because plaintiff failed to provide <u>any</u> support for the underlying scientific theory that constipation in general, whether or acute or chronic, can cause a cecal volvulus, the trial court granted summary judgment.

The medical literature that plaintiff provided does not support Dr. Brentnall's opinion.[3] CP 485 (citing CP 524-33, 535-44). The first article is titled "Management of the Colonic Volvulus in 2016." CP 524-533. As the title suggests, the article almost exclusively discusses management and treatment of colonic volvulus and not the causation of the colonic volvulus – *i.e.* what to do <u>after</u> the condition occurs, not <u>how</u> the condition occurs. To the extent the article discusses

---

[3] Plaintiff also cites to two abstracts of scientific articles, without further discussion. CP 535-537. Abstracts of scientific articles are not themselves scientific literature. It is unknown who wrote the abstracts or what those articles say. Regardless, both abstracts are unhelpful because they do little more than mention a correlation between constipation and a cecal volvulus, not causation. That is, neither abstract discusses which comes first, a cecal volvulus or constipation.

constipation at all, it only identifies it as one of several risk factors, including a high fiber diet, frequent use of laxatives, history of laparotomy, and anatomic predisposition. CP 525. Designation of constipation as a risk factor is not proof of causation. Correlation is not causation.

The second article, "Colonic Atony in Association with Sigmoid Volvulus: It's Role in Recurrence of Obstructive Symptoms," is also insufficient. CP 583. First, the article concerns a sigmoid volvulus, not a cecal volvulus. Second, the article raises a "chicken/egg" issue by noting that science has yet to explain which occurs first. It states that megacolon (a stretched out colon) could cause chronic constipation or chronic constipation could cause megacolon:

> Chronic constipation is a common malady that can have various causes . . . the underlying cause of the megacolon and constipation . . . is unknown, and it has not been demonstrated which comes first—megacolon or constipation.

CP 539.

At best, the scientific community has concluded that chronic constipation's role in cecal volvulus formation presents a causality

dilemma, with neither constipation nor megacolon more likely than not causing the other. As a result, as the trial court aptly concluded, "the literature that has been provided doesn't come close to answering [whether constipation can cause a cecal volvulus]." *Id.*

On appeal, plaintiff simply provides a conclusory statement that Dr. Brentnall's opinion is "supported by known facts regarding the anatomy of the colon and by the presence of a large amount of stool in the colon," and by scientific literature. Opening Brief, pp. 7, 9 (internal citations omitted). Because both of plaintiff's scientific articles fail to support the underlying scientific theory that constipation in general, whether acute or chronic, can cause a cecal volvulus, it cannot be said that the scientific theory is generally accepted in the scientific community.

iii. Because Dr. Brentnall's scientific theory is unsupported, her differential diagnosis cannot support her opinion.

The lack of general consensus regarding Dr. Brentnall's underlying scientific theory requires affirmance of the trial court's order. Plaintiff seeks to save her case by repeatedly referring to the differential diagnosis that Dr. Brentnall used to form her ultimate conclusion that constipation caused Ms. Ritter's death, but a

differential diagnosis is only as good as the potential "causes" that are considered in the diagnosis.

In performing a differential diagnosis, a physician opines as to the cause of a particular injury or symptom by working through a process of elimination based on a list of potential causes. Defendant agrees that a differential diagnosis generally is an acceptable way to rule out various causes for an injury, but it is not acceptable in this case because, in performing her differential diagnosis, Dr. Brentnall took a flawed scientific theory into account – constipation as a potential cause for a cecal volvulus.[4]

Accordingly, the trial court did not err in granting summary judgment in favor of defendants.

---

[4] Dr. Brentnall's differential diagnosis is also flawed because it was not based on the complete factual record, making her expert testimony even more unreliable and irrelevant. For example, during her deposition, Dr. Brentnall testified that adhesions can also cause a cecal volvulus but that she did not consider adhesions as an alternative cause of the cecal volvulus "because there was no evidence of adhesions per the operative notes following Ms. Ritter's surgery on 9/2/14." CP 485. However, defendants provided evidence of adhesions from Dr. Yancey Sloane's report dated that same day. CP 409.

V. CONCLUSION

The trial court did not apply *Frye* to plaintiff's expert witness's ultimate opinion on causation; rather, the trial court explicitly held that plaintiff failed to show general acceptance of the scientific theory underlying her expert witness's opinion. As a result, plaintiff lacked admissible expert testimony regarding causation. Accordingly, the trial court granted summary judgment. This court should affirm.

Respectfully Submitted this 26th day of January, 2018.

HART WAGNER LLP

By: */s/ Matthew J. Kalmanson*

Matthew J. Kalmanson, WSB No. 41262
Of Attorneys for Respondents

APPENDIX

Journal of Visceral Surgery (2016) 153, 183–192

Available online at
ScienceDirect
www.sciencedirect.com

Elsevier Masson France
EM|consulte
www.em-consulte.com/en

REVIEW

Management of the colonic volvulus in 2016

L. Perrot[a,*], A. Fohlen[b], A. Alves[a], J. Lubrano[a]

[a] *Service de chirurgie viscérale et digestive, centre hospitalier régional et universitaire, avenue de la Côte-de-Nacre, 14000 Caen, France*
[b] *Service de radiologie, centre hospitalier régional et universitaire, avenue de la Côte-de-Nacre, 14000 Caen, France*

Available online 28 April 2016

KEYWORDS
Volvulus;
Colon;
Cecum;
Sigmoid;
Endoscopy

Summary Colonic volvulus is the third leading cause of colonic obstruction worldwide, occurring at two principal locations: the sigmoid colon and cecum. In Western countries, sigmoid volvulus preferentially affects elderly men whereas cecal volvulus affects younger women. Some risk factors, such as chronic constipation, high-fiber diet, frequent use of laxatives, personal past history of laparotomy and anatomic predispositions, are common to both locations. Clinical symptomatology is non-specific, including a combination of abdominal pain, gaseous distention, and bowel obstruction. Abdominopelvic computerized tomography is currently the gold standard examination, allowing positive diagnosis as well as detection of complications. Specific management depends on the location, patient comorbidities and colonic wall viability, but treatment is an emergency in every case. If clinical or radiological signs of gravity are present, emergency surgery is mandatory, but is associated with high morbidity and mortality rates. For sigmoid volvulus without criteria of gravity, the ideal strategy is an endoscopic detorsion procedure followed, within 2 to 5 days, by surgery that includes a sigmoid colectomy with primary anastomosis. Exclusively endoscopic therapy must be reserved for patients who are at excessive risk for surgical intervention. In cecal volvulus, endoscopy has no role and surgery is the rule.
© 2016 Elsevier Masson SAS. All rights reserved.

Introduction

The term "volvulus" comes from the Latin "volvere" meaning twist. It was first described by Rokitansky in 1836 [1]. Colonic volvulus is the third leading cause of colonic obstruction in the world, following colorectal cancer and complicated sigmoid diverticulitis [2]. Any mobile segment of the colon can be affected by volvulus [3]. According to various series in the literature, the sigmoid is involved in 60–75% of cases, cecum in 25–40% of cases, transverse colon in 1–4% of cases and splenic flexure in 1% of cases. There are numerous publications in the literature, but many of these are dated, have low numbers of patients and inadequate follow-up. The aim of this review is to build a decision algorithm for diagnostic and therapeutic management of colon volvulus. After a brief review of the epidemiology and etiology of colon volvulus, we discuss common and specific points of the diagnosis and treatment of sigmoid and cecal volvulus.

Epidemiology

The incidence of colon volvulus varies in different regions of the world. Thus, in the so-called "volvulus belt", an endemic area that includes Africa, South America, Russia, Eastern Europe, the Middle East, India and Brazil, colonic volvulus represents 13 to 42% of all intestinal obstructions

* Corresponding author.
E-mail address: laurentperrot@hotmail.com (L. Perrot).

http://dx.doi.org/10.1016/j.jviscsurg.2016.03.006
1878-7886/© 2016 Elsevier Masson SAS. All rights reserved.

[4–7]. In "Western" countries where the incidence is low (North America, Western Europe, Australia), colonic volvulus represents less than 5% of all intestinal obstruction. The latest large-scale epidemiological study, published by Halabi et al. [8], reported on 63,749 cases of colonic volvulus among 3,351,152 cases of intestinal obstruction over a 9-year period. During this period, the authors observed a stable incidence of sigmoid volvulus, however, the incidence of cecal volvulus increased by 5% per year.

Similarly, the volvulus location and its clinical setting vary by region. In the "volvulus belt" countries, sigmoid volvulus usually occurs in young men (from the 4th decade onward with a male:female sex-ratio of 4:1). For this reason, some authors consider that endemic sigmoid volvulus is a different clinical entity than sporadic volvulus [9]. In Western countries, sigmoid volvulus preferentially affects elderly males (age > 70) while cecal volvulus affects somewhat younger females (age ≤ 60), as highlighted in the study by Halabi et al. [8].

Etiology

The etiology of colon volvulus is probably multifactorial. Some factors are common to all locations of volvulus, such as chronic constipation, high fiber diet, frequent use of laxatives, history of laparotomy and anatomic predisposition.

Dolicho-sigmoid, the presence of an elongated sigmoid colon on a narrow mesenteric base, is the most commonly cited predisposing factor for sigmoid volvulus. An anatomical study performed on 590 cadavers demonstrated ethnic anatomical differences [10]. The length and height of the sigmoid were significantly longer and the root of the mesosigmoid narrower in Africans, with no difference between men and women. In the case-control study of Akinkuotu et al. [11], there was a significant increase in the length of the mesosigmoid, the maximum width of the mesosigmoid and the lumenal circumference of the colon in patients who underwent surgery for sigmoid volvulus. However, there was no significant difference in the maximal width of the mesosigmoid root. The authors concluded that the combination of a high and wide mesosigmoid with a narrow root predisposed to sigmoid volvulus. While there are clearly anatomical predispositions, it remains unclear whether they are congenital or acquired [12].

Anatomical predispositions have also been reported for cecal volvulus. Thus, cecal volvulus may be linked to failure of parietal fixation of the ileocecal region during embryological counterclockwise cecal rotation from the left side of the abdomen towards the right iliac fossa. In an autopsy series of 125 cadavers, Ballantyne et al. observed a complete absence of ileocecal attachment in 11% of cases and cecal hypermobility allowing rotation in 26% of cases [2].

Some risk factors are more specific to cecal volvulus such as history of previous colonoscopy, laparoscopy and pregnancy [13]. Other risk factors favor the development of sigmoid volvulus, such as diabetes, neuropsychiatric history leading to reduced autonomy, institutional placement and prolonged bed rest. Finally, in younger patients, sigmoid volvulus is often associated with megacolon due to such causes as Hirschsprung's or Chagas disease [4].

Pathophysiology

In sigmoid volvulus, mesosigmoid twisting of up to 180° is considered physiological. In approximately 2% of cases, the volvulus reduces spontaneously [2]. Torsion beyond 180° leads to complications such as colonic obstruction, ischemia or necrosis with perforation. For unknown reasons, the twist preferentially occurs in the counterclockwise direction in 70% of cases [14]. Fibrosis of the mesosigmoid, seen in 86% of operated patients, is more a result than a cause of the torsion, due to cicatrization after reversible ischemia in the relapsing forms of volvulus [15]. During sigmoid volvulus, colonic distension causes an increase in intralumenal pressure, which results in decreased capillary perfusion; this mural ischemia is aggravated by mesocolic vessel occlusion by mechanical phenomena of compression and axial rotation [16]. Early mucosal ischemia promotes bacterial translocation and bacterial gas production, further increasing colonic distension and toxic phenomena. If colonic torsion is not promptly reversed, this creates a vicious circle leading to colonic necrosis and ischemia-reperfusion. These phenomena result in a state of mixed septic and cardiovascular shock. Figs. 1 and 2 describe the two mechanisms of torsion in sigmoid volvulus, with axial mesocolic volvulus being more common than organo-axial volvulus (75% vs. 25% [17]).

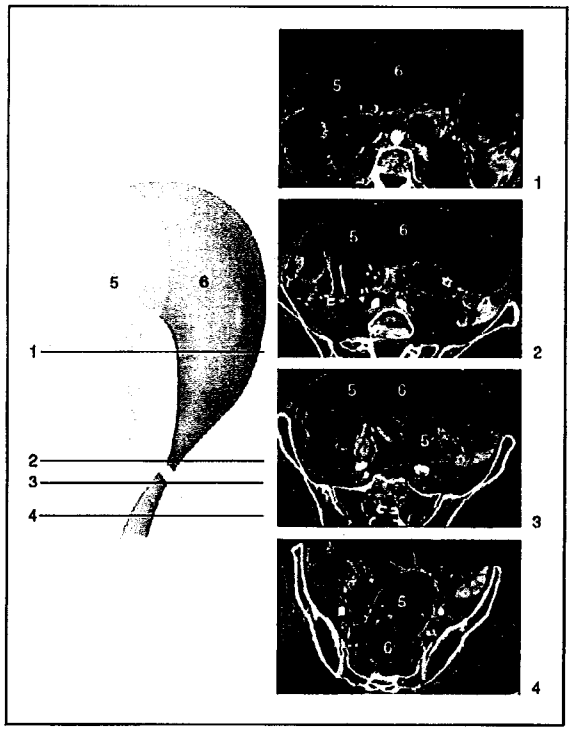

Figure 1. Mesenterico-axial sigmoid volvulus: CT appearance. Slices 1 through 4 are localized on the schematic drawing. Identified points 5 and 6: 5: proximal limb; 6: distal limb.
Image from Lubrano et al. [17], © 2012 Elsevier Masson SAS. All rights reserved.

There are two distinct anatomical types of cecal volvulus (Fig. 3): axial rotation of the ileocecal region around its mesentery, generally in a clockwise direction (90%) and anterior-superior folding of the cecum without axial rotation, commonly called cecal bascule [4]. Cecal bascule is less common than true rotation of the ileocecal region and causes less vascular compromise since there is no true mesenteric torsion [18].

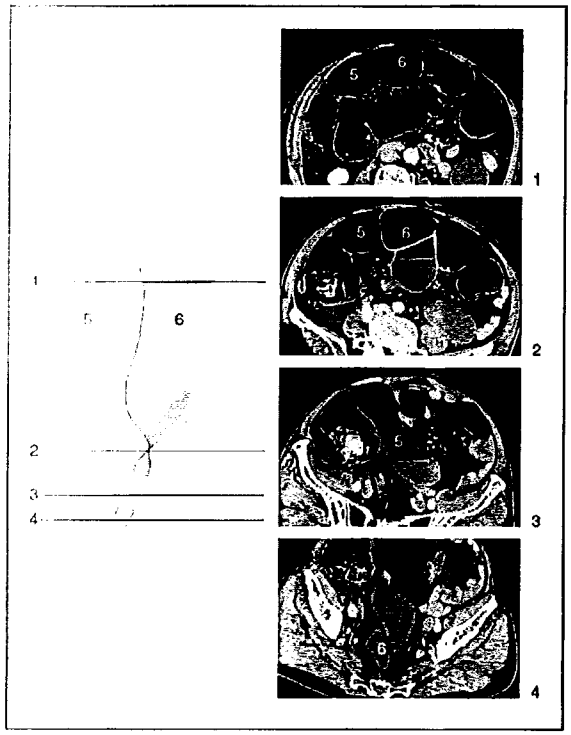

Figure 2. Organo-axial sigmoid volvulus: CT appearance. Slices 1 through 4 are localized on the schematic drawing. Identified points 5 and 6: 5: proximal limb; 6: distal limb.
Image from Lubrano et al. [17], © 2012 Elsevier Masson SAS. All rights reserved.

Clinical symptomatology

At whatever site colonic volvulus occurs, clinical symptomatology is non-specific. Sigmoid volvulus presents with a clinical triad of abdominal distension, low abdominal crampy pain with constipation, and vomiting (usually a late symptom). In 30–41% of cases, patients report previous episodes of abdominal distention [4]. This triad is more common in endemic than sporadic volvulus (88% versus 33%) [19]. In the "volvulus belt" countries, the clinical presentation may be acute with peritonitis and shock. In this fulminant clinical presentation, the prognosis is poor because colonic necrosis and perforation have already occurred by the time the patient first presents for care [20].

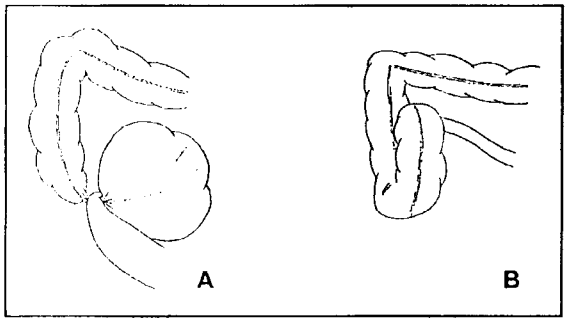

Figure 3. Anatomic types of cecal volvulus. A. Ileocecal volvulus. B. Cecal bascule.

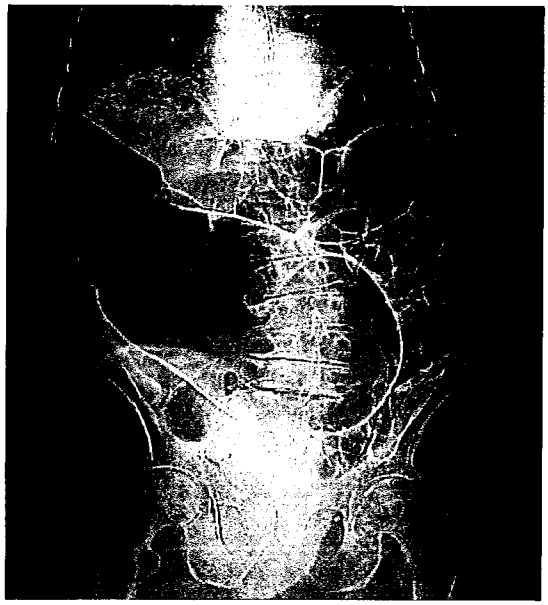

Figure 4. Sigmoid volvulus: abdominal plain X-ray. Coffee bean-shaped image corresponding to the two limbs of the volvulized segment, the top of the loop riding up into the right subcostal region.

Conversely, in Western countries, the patient usually presents 3 to 4 days after the onset of symptoms [21]. The classic patient is elderly, institutionalized, and under psychotropic medications that cause chronic constipation. The history should elicit the above-mentioned risk factors, including a personal history of previous sigmoid volvulus, which is present in 30–40% of cases. Initial clinical examination is often difficult due to abdominal distension associated with colonic obstruction of several days duration; if there are no signs of peritoneal irritation, as is often the case, this may result in a delay in diagnosis. Classically, asymmetric gaseous abdominal distention associated with emptiness of the left iliac fossa is pathognomonic for sigmoid volvulus [6].

In cecal volvulus, the clinical presentation is also non-specific, combining in varying degrees: intermittent episodes of abdominal distension, crampy abdominal pain, constipation, nausea and vomiting. In the "mobile cecum syndrome", these episodes may spontaneously resolve and then recur [22]. Typically, the pain resolves along with resumption of intestinal transit. In other cases, cecal volvulus may present with a picture of acute intestinal obstruction.

Laboratory tests do not point specifically to the diagnosis. They are only a reflection of bowel obstruction and/or sepsis: fluid and electrolyte disorders, hypokalemia, azotemia, leukocytosis, inflammatory syndrome, or even bleeding disorders when bowel necrosis is present.

Imaging

In the past, abdominal plain X-rays (Fig. 4) and water-soluble contrast enema were the key diagnostic examinations.

Currently, these two techniques have been virtually abandoned in favor of CT scan, particularly for the initial episode where CT will confirm the diagnosis with near

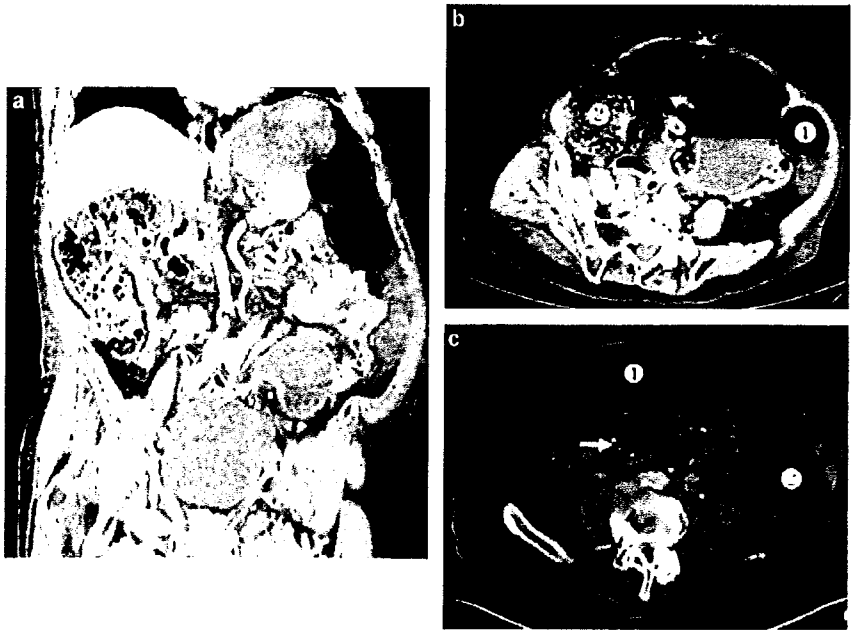

Figure 5. CT signs of sigmoid volvulus: a: arrow: "bird's beak" sign at the junction of the torsed loop and the point of torsion; b: arrow: "bird's beak" sign at the junction of the dilated loop and the zone of torsion: 1: air-filled dilated left colon proximal to the volvulus; 2: copious fecal loading of the cecum; c: arrow: "whirl sign": 1: air-filled volvulized loop, with a virtual wall; 2: dilated left colon upstream from the volvulus with air-fluid levels.

100% sensitivity and >90% specificity [23,24]. Due to its volume acquisition, CT allows multiplanar reconstruction that facilitates definitive diagnosis.

It also eliminates other possibilities from the differential diagnosis, particularly obstructing colorectal carcinoma at the rectosigmoid junction.

Numerous characteristic findings on CT scan have been described in the literature, including the "bird's beak" appearance created by the two limbs of the twisted colonic segment joining at the point of torsion, or a "coffee bean" image on the frontal reconstruction (Fig. 5), which is also often evident on abdominal plain films (Fig. 4), corresponding to the loop of the volvulized sigmoid.

A "swirl" or "whirl" sign has also been described, corresponding to the point of torsion around which the bowel loops and mesenteric vessels are wrapped (Figs. 5 and 6), and the "X-marks-the-spot sign", corresponding to transition points of each limb crossing at the same place, and the "split wall sign" linked to a tomographic image of the sigmoid loop wrapped around its mesentery that sometimes gives the impression of two separate digestive structures.

CT can also show indirect signs such as dilated proximal intestine and colon when the ileocecal valve is incompetent, and an absence of air in the distal colon and rectum. It can identify the transition zone between dilated and empty intestine.

A final but crucial benefit of CT is its ability to detect signs of gravity, which may modify the therapeutic management approach:

- degree of colonic distension;
- especially, direct signs of intestinal ischemia in the wall of the twisted loop: spontaneous hyperdensity, enhancement defect after contrast injection with or without pneumatosis intestinalis (arterial ischemia), or wall thickening (venous ischemia);
- indirect signs of intestinal ischemia: free peritoneal fluid or mesenteric or portal venous air;
- mesenteric injury with hyperemia or mesenteric hematoma;
- pneumoperitoneum, signaling perforation of the twisted loop.

Treatment strategy

Therapeutic strategy depends on the location of the volvulus, clinical presentation and initial paraclinical findings. Complicated forms must be quickly diagnosed and brought promptly to surgery regardless of location. For complicated forms of volvulus, the therapeutic strategy differs depending on the location of the volvulus and patient condition; the medium-term challenge is to limit recurrent episodes of volvulus.

Complicated forms of volvulus

What is the appropriate gesture?

Whatever the location of colon volvulus, criteria of clinical severity and/or radiological evidence of a colonic necrosis or perforation, with or without signs of shock, demand surgical treatment from the outset. After correction of fluid and electrolyte deficits, clotting abnormalities, and stabilization of the patient's condition (restoration of vascular volume...), surgery consists of midline laparotomy with resection of the necrotic bowel segment. Whether or not to restore intestinal continuity depends on local conditions and the patient's hemodynamic status.

The incidence of colonic necrosis varies depending on the series. Thus, in a Turkish series [25], 271 patients (61%) had a sigmoid volvulus complicated by colonic necrosis.

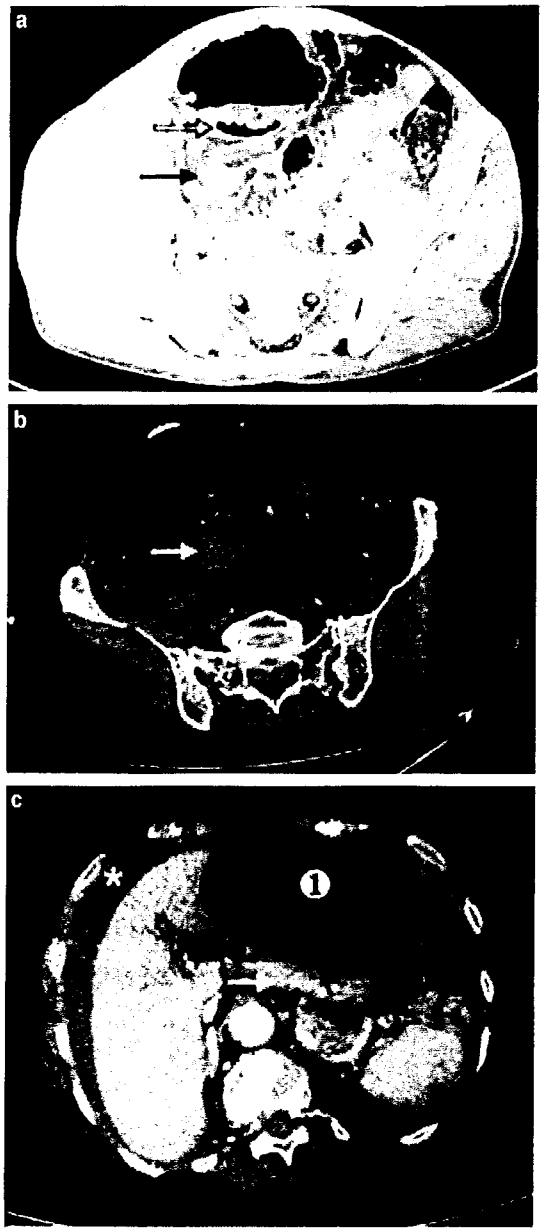

Figure 6. CT signs of complications due to cecal volvulus: a: black arrow: "whirl sign", hollow arrow: pneumatosis intestinalis of the volvulized loop, considered a precursor sign of perforation; b: white arrow: spontaneous hyperdensity corresponding to a mesenteric hematoma; c: 1: dilated volvulized loop in an ectopic position, riding up into the left subcostal area; star: peri-hepatic free fluid indicative of intestinal ischemia, white arrow: stomach displaced posteriorly by the volvulized loop.

Severe comorbidities (chronic obstructive pulmonary disease, hypertension, ischemic heart disease, heart failure, diabetes, chronic renal failure, hemiplegia, Parkinsonism), the presence of shock, prolonged duration of symptoms, and combined colonic and ileal volvulus were significantly associated with risk of colonic necrosis. However, no correlation was confirmed between patient age and/or prior history of sigmoid volvulus and colonic necrosis [6,25,26].

Colonic necrosis and peritonitis are the two main risk factors for mortality [6,8,27,28].

Should intestinal continuity be restored at the initial intervention?

For cecal volvulus, immediate restoration of intestinal continuity can be performed by a stapled side-to-side ileocolic anastomosis, as long as there is no peritoneal contamination [29].

The strategy differs for sigmoid volvulus. Restoration of continuity is controversial even in the absence of peritoneal contamination. Indeed, the presence of a dilated and stool-laden proximal colon increases the risk of postoperative anastomotic leak. Some studies have nevertheless argued in favor of restoration of continuity in the absence of peritoneal contamination. In the series of Oren et al. [30], there was no significant difference in mortality after Hartmann procedure (22%) versus resection with anastomosis (19%) among patients who underwent surgery for complicated volvulus.

Moreover, the performance of intraoperative colonic lavage resulted in a decreased 9% mortality in the segmental resection group. Caution still seems to be the rule and it seems legitimate to encourage colostomy if there are adverse local or systemic conditions, or if the surgeon's experience in colorectal surgery is limited.

If sigmoid resection with colostomy is performed, two techniques are possible: a Hartmann procedure or a double-barrel colostomy in the left iliac fossa as described by Bouilly-Volkman and Mikulicz-Radecki. The advantage of the double-barrel colostomy is that it allows monitoring of the downstream colonic segment in the acute phase and allows a simpler restoration of continuity as a delayed elective procedure. Sigmoid resection at the rectosigmoid junction seems to not be effective in preventing further recurrence of volvulus, which is why the double-barrel colostomy seems to be the ideal gesture when technically feasible. The Hartmann procedure should be reserved for cases of low volvulus with colonic necrosis extending to the rectosigmoid junction making it impossible to bring the distal colonic segment up to the skin level.

Uncomplicated volvulus

If there are no criteria of gravity, the therapeutic strategy for cecal volvulus is different from that for sigmoid volvulus.

Uncomplicated sigmoid volvulus

Initial management

For uncomplicated sigmoid volvulus, colonoscopy is the initial gesture for both diagnosis and treatment. Endoscopy allows one to not only assess the viability of the sigmoid but also to achieve detorsion of the volvulus. If colonic necrosis is present, the patient undergoes immediate surgery. In the absence of colonic necrosis, endoscopy can convert an urgent situation into an elective situation. Colonoscopic detorsion is a relatively simple, minimally invasive procedure associated with a success rate of 70 to 95% with a 4% morbidity. However, mortality is not zero and has been almost 3% in recent series [27,30,31]. A successful procedure results in decompression of gas and evacuation of stool.

The literature favors flexible endoscopy over rigid endoscopy because of its superior diagnostic performance, particularly in assessing ischemia and because of its lower perforation rate [31]. Indeed rigid sigmoidoscopy can fail to diagnose sigmoid volvulus and especially ischemia in up to

24% of cases. After endoscopic decompression, a Faucher rectal tube is left in place for a variable period from 36 to 72 hours.

The favorable impact of colonoscopy is perfectly illustrated in Turkey's very large retrospective series that compiled 952 patients over a period of 46.5 years [30]. Colonic decompression has evolved from initial use of barium enema (1966–1968), to rigid sigmoidoscopy (1968–1988), to the introduction of the flexible endoscope in 1988, and exclusive use of flexible endoscopic decompression from 2003 onward. In the Turkish experience, barium enema resulted in successful decompression in 69% of cases but was burdened with a morbidity of 23%, a mortality of 8% and early recurrence in 11% of cases. With rigid sigmoidoscopy, the authors observed successful decompression, morbidity, mortality and early recurrence rates of 78%, 3%, 1% and 3%, respectively. With the advent of flexible endoscopy, rates of successful decompression, morbidity, mortality and early recurrence were 76%, 2%, 0.3% and 6%, respectively.

Barium enema should no longer be considered because it has been replaced by flexible endoscopy.

Is there a need for total colonoscopy?

There seems to be little place for screening colonoscopy before surgery, mainly because of its technical difficulty. Indeed, bowel preparation is usually not feasible and the colon is often extremely long due to the presence of a megacolon or dolichocolon with angulations that are difficult to traverse. Preoperative total colonoscopy should be offered only if there is clinical or radiological suspicion of underlying neoplasia [32–34].

Endoscopy is therefore limited in most cases to short flexible colonoscopy performed during endoscopic detorsion, which also rules out neoplastic obstruction the rectosigmoid junction, the other principal entity in the differential diagnosis. In case of diagnostic uncertainty, a virtual colonography can be performed instead of total colonoscopy.

What treatment after endoscopic detorsion?

After colonoscopic detorsion followed by conservative management, the recurrence rate of sigmoid volvulus varies from 45% to 71% [27,32–35]. This tendency persists in recently published studies both in France (67% in the experience of the Saint-Antoine hospital [21]), Turkey (nearly 2 out of 3 patients with follow-up exceeding 40 years), New Zealand (61% at 3 months [36]) or in the Danish registry with recurrence probability of 63%, 47%, 41% and 24%, respectively at 3, 6, 12 and 24 months [37]. In addition, the mortality after conservative treatment in the literature varies between 9 and 36% [27,32–35]. In the Danish registry, survival was significantly lower after conservative treatment [38]. However, these results must be qualified since patients considered non-surgical from the start were significantly older and had a significantly higher ASA score (82 vs. 71, $P=0.004$; ASA 3 vs. ASA 2, $P=0.012$).

In the absence of a randomized study, the current consensus is to perform colonic resection within 2 to 5 days of endoscopic detorsion after the first episode of sigmoid volvulus, because of the high risk of recurrence [39]. For example, only 17% of patients in the study by Halabi et al. had exclusively conservative treatment [8].

Recently, development of percutaneous endoscopic colostomy has been proposed in order to avoid recurrence after decompression and several authors have reported its feasibility [40–43]. This minimally invasive technique has been performed mainly in elderly patients with severe comorbidity or institutionalized patients [21]. Although the reported morbidity and mortality is low, these results must be qualified because of the small number of patients included. However, percutaneous endoscopic colostomy appears as an attractive minimally invasive alternative for debilitated patients that does not require general anesthesia.

What surgical management?

In the absence of a randomized study, the type of surgical treatment remains controversial, although colonic resection with restoration of continuity is the standard treatment [4,8,44].

Whatever the location of the colonic volvulus, several alternatives to resection exist such as detorsion without resection, colopexy, and colostomy. However, these gestures all entail a high risk of recurrence as highlighted in several studies in the literature. Thus, the risk of recurrence varied from 9% to 44% after detorsion without resection volvulus [20,30,45,46] and 20–30% after colopexy [30,44,47].

In France, the mortality risk after elective colonic surgery is close to 2% with a morbidity between 20 and 30%. Two French multicenter studies evaluated the mortality risk factors. Both studies found the same four risk factors: urgent surgery, age > 70 years, malnutrition (weight loss > 10% of body weight in less than 6 months), and neurological impairment. These factors are included in the score developed by the French Association of Surgery (AFC) [48]. Knowledge of these risk factors is used to assist practitioners in the management of operative risk.

Several series have reported the results of surgical treatment of colon volvulus but these figures are difficult to analyze because of the age of the studies, low numbers and heterogeneous procedures. The recent study by Halabi et al. [8] compiling 63,749 cases illustrates the evolution of surgical practices in the treatment of colon volvulus. Among surgical patients (83%), detorsion without colonic fixation was performed in 4% of surgical cases and was associated with 8% mortality. Colonic fixation (colopexy) was used in 3% of cases and was associated with 3% mortality; cecostomy or sigmoid colostomy was used in 3% of cases and was associated with a mortality of 13%. Colonic resection was the most frequently performed procedure (89% of cases), with a mortality of 9% for sigmoid volvulus and 6% for cecal volvulus. In 16% of cases, a subtotal colectomy was performed because of either a double volvulus, a volvulus of the transverse colon, or extensive colonic ischemia, with a 15% mortality. The two main risk factors for mortality after surgical treatment of sigmoid volvulus were peritonitis and colonic necrosis. Outside the emergency setting, other risk factors were age > 70 years, coagulopathy, cardiorespiratory disease and renal comorbidities (8).

These elevated complication rates should be put into perspective with other recent publications. Thus, the group of the Saint-Antoine hospital [21] had a mortality rate of zero and a 6% morbidity in 33 patients who underwent sigmoid resection for sigmoid volvulus.

Finally, the recurrence rate is strongly linked to the type of procedure: it can be up to 44% after detorsion alone and 30% after detorsion with colopexy [8], while it is less than 10% after colonic resection [21]. This confirms the superiority of resection compared to other surgical techniques.

Extension of the colonic resection

Non oncologic resection of the sigmoid loop is generally sufficient, completed by colorectal anastomosis without mobilization of the splenic flexure. But an extended resection may be necessary in the case of extension of colonic necrosis or in the case of associated colonic atony or megacolon [49]. Some authors recommend performance of a subtotal colectomy in case of associated megacolon because of the high risk of recurrence [13,50,51]. In the experience of Morrissey and Deitch [52], the mean rate of recurrence after left colonic resection was 37%; it was only 6% when only the sigmoid was involved vs. 82% if there was associated megacolon. Such an extensive resection may also be necessary in case of double volvulus [8]. In all cases, there is no need for oncologic resection of the root of the mesentery and lymph node dissection.

Which surgical approach?

For elective surgical therapy for sigmoid volvulus, a left-sided McBurney incision or a Pfannenstiel incision seem to be the incisions of choice, although a low midline laparotomy is an alternative.

Scant data are currently available in the literature concerning the role of laparoscopy. However, the absence of fixation of the sigmoid colon and its excessive length often make laparoscopic exposure and dissection difficult, and its interest is further limited since resection with or without anastomosis does not require mobilization of the descending colon.

One retrospective study compared the results of laparoscopy and laparotomy in the management of sigmoid volvulus [53]. Morbidity, the rate of anastomotic leakage and length of hospital stay were similar between the two groups. Only the rate of recurrent volvulus was higher in the laparoscopic group (12 vs. 0%). In the US study by Halabi et al. [8], laparoscopy was performed in 4% of surgical procedures, but with increasing frequency over the past 3 years, especially in young patients with low comorbidity scores. In all cases, whether involving colopexy, colostomy, or resection, the observed mortality was lower for laparoscopy than for laparotomy (3.0% vs. 3.3% for colopexy, 7 vs. 13% for colostomy, 5 vs. 7% for right colectomy, 2 vs. 10% for sigmoid colectomy, 12 vs. 15% for total colectomy). We cannot yet recommend the laparoscopic approach for colonic volvulus, due to the small number of studies.

Cecal volvulus

In cecal volvulus, colonoscopy is not recommended due to its low efficacy of about 30% [29,54].

Cecal volvulus should be considered a surgical emergency, even when there are no clinical or radiological criteria of gravity. Treatment consists of midline laparotomy with a non-oncological colectomy of the volvulized segment (i.e., usually an ileocecal resection) and immediate restoration of continuity. Depending on the extent of right colon ischemia, the resection may need to be extended to include the right colon. A side-to-side stapled anastomosis seems to be ideal because it accomodates the lumenal disparity between the ileum and right colon.

Detorsion and colopexy fixation without resection is associated with a high recurrence rate and significant morbidity and mortality; it seems to have no place [8].

Laparoscopy is technically impractical due to bowel obstruction, often with significant distension of the volvulized loop and proximal intestine; it is not a recommended approach.

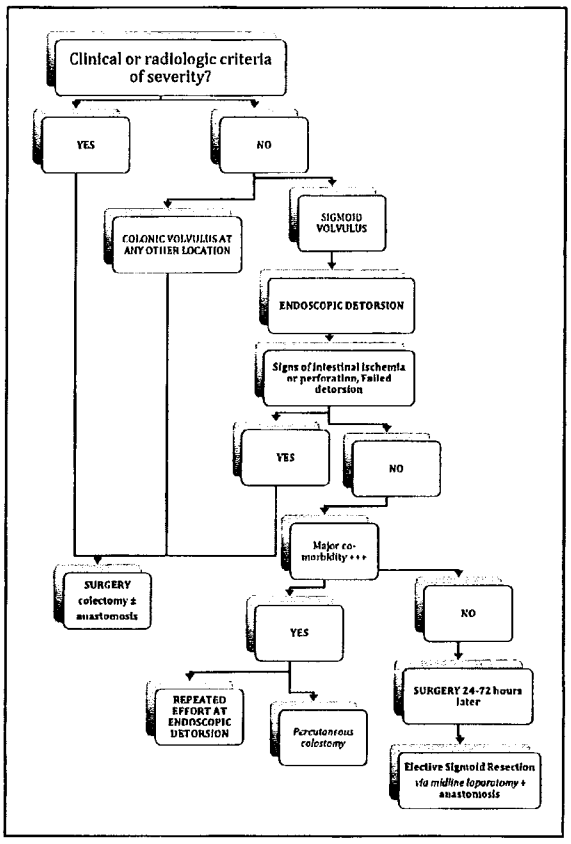

Figure 7. Management strategy for colonic volvulus: decisional algorithm.

The surgical management of colonic volvulus is summarized in an algorithm (Fig. 7).

Special cases

Colonic volvulus and pregnancy

Colonic volvulus is the first or second leading cause of organic bowel obstruction in pregnant women, although very few cases have been reported in the literature (about a hundred). Both diagnosis and treatment pose problems that may threaten both the maternal and especially the fetal prognosis. It typically occurs in a multiparous woman (in 75% of cases), and in the 3rd trimester in two-thirds of cases [24]. The clinical and laboratory abnormalities are non-specific. Maternal and fetal prognosis are both worsened by delay in diagnosis that can lead to colonic necrosis in 23% of cases [55]. Choice of imaging modalities depends on the term of the pregnancy but magnetic resonance imaging may be an attractive option [56]. For uncomplicated sigmoid volvulus, endoscopic detorsion is recommended but may be ineffective especially in the third trimester because of the volume of the uterus.

The multidisciplinary strategy will therefore depend on the term of pregnancy and the fetal prognosis. In ideal circumstances, definitive surgery is recommended after

childbirth, but can be performed without significant impact from the second trimester onward.

The reported rates of maternal and fetal mortality are 6–12% and 20–26% respectively [55].

Uncommon types: volvulus of the transverse colon and splenic flexure

These types of volvulus are extremely rare. They affect mostly young patients in the second or third decade, preferentially women [4].

Transverse colon volvulus is favored by chronic constipation, resulting in colonic elongation, and by defects in mesenteric fixation. Volvulus of the splenic flexure is favored by chronic constipation, history of abdominal surgery and the Chilaiditi syndrome, (interposition of a colonic segment [usually transverse] between the liver and the right diaphragm). The clinical picture is one of acute colonic obstruction. An episode can resolve spontaneously or can evolve with intermittent episodes of obstruction. Diagnosis currently relies on abdominopelvic CT. The rarity of volvulus at these locations and difficulties in diagnosis often lead to delays in management with a high mortality rate of 33% [57].

Treatment consists of resection, typically an extended right hemicolectomy or segmental transverse colectomy, with performance of an anastomosis if local conditions and patient comorbidities permit [4].

Simple detorsion has no place since it is associated with a significant recurrence rate and a high mortality.

Exceptionally rare: ileosigmoid volvulus

Ileosigmoid volvulus is exceptional, although near endemic in the "volvulus belt" of Africa, Asia and the Middle East. Affected patients are usually young men (4th to 5th decade) [58]. Three types of ileosigmoid volvulus have been described:

- type I: the ileum wraps around the sigmoid clockwise or anti-clockwise (about 55% of cases);
- type II: sigmoid wraps around the ileum clockwise or counterclockwise (about 5% of cases);
- type III: the ileocecal region wraps around the sigmoid (less than 5% of cases).

There are some unclassifiable variants; the rotation is clockwise in about 2/3 of cases [58].

The clinical picture is an acute onset of bowel obstruction, often with systemic toxicity and frequently, there is treatment delay. Indeed, the diagnosis is made in only 20% of cases and intestinal necrosis of the ileum and/or sigmoid colon is observed in 70% of cases. Diagnosis currently relies on abdominopelvic CT. The therapeutic management requires fluid and electrolyte resuscitation followed by surgery: double resection with or without restoration of continuity depending on the operating findings. Mortality is high, reaching 73% in some series [59].

Conclusions

Colonic volvulus, the third most common cause of colonic obstruction, is a medical and surgical emergency; in Western countries, it usually occurs in the elderly, institutionalized patient with a neuropsychiatric history, and is often associated with diagnostic and therapeutic delay. Abdominopelvic CT is essential for definitive diagnosis and detection of signs of severity. When signs of complications such as necrosis or peritonitis are present, immediate surgical treatment consists of colonic resection usually without restoration of continuity. In the absence of criteria of severity, the therapeutic strategy depends on the location of volvulus.

For cecal volvulus, right colectomy is currently recommended; the decision for or against immediate restoration of continuity depends on the operating findings and the patient's general condition (comorbidities, AFC score).

For uncomplicated sigmoid volvulus, colonoscopy is the first-line procedure for both diagnosis and therapy; it allows assessment of colon viability and detorsion of the volvulus. Staged sigmoid resection is performed within 2 to 5 days of endoscopic detorsion. Currently, surgical detorsion without resection, colopexy, and/or colostomy are no longer recommended because of the high risk of recurrence and mortality. However, the treatment strategy remains controversial for high-risk patients; the innovative technique of percutaneous endoscopic colostomy could be a minimally invasive alternative that reduces not only the risk of recurrence but also of mortality.

Keypoints

- Colonic volvulus is a medical and surgical emergency that involves the sigmoid colon in 60–75% of cases and the cecum in 25–40% of cases.
- In Western countries, sigmoid volvulus usually occurs in the elderly, institutionalized patient with neuropsychiatric history.
- Abdominopelvic CT scan is the essential test for definitive diagnosis and assessment of gravity.
- In colonic volvulus with signs of complication (colonic necrosis, perforation, shock), immediate colectomy is required, usually without restoration of continuity.
- In cecal volvulus, right colectomy is recommended; the timing of restoration of continuity depends on the operative findings and the patient's general condition.
- In uncomplicated sigmoid volvulus, colonoscopy is the first-line procedure to assess colon viability and detorse the volvulus. Staged sigmoid resection is performed within 2 to 5 days of endoscopic detorsion.
- Other surgical strategies (detorsion without resection, colopexy and/or colostomy) are contraindicated because of their high risk of recurrent volvulus and mortality.
- For high-risk patients, the treatment strategy is still controversial; percutaneous endoscopic colostomy may be a minimally invasive alternative to surgery that could reduce the risk of recurrence and mortality.

Disclosure of interest

The authors declare that they have no competing interest.

References

[1] Tan PY, Corman ML. History of colonic volvulus. Semin Colon Rectal Surg 1999;10:122–8.

[2] Ballantyne GH, Brandner MD, Beart RW, Ilstrup DM. Volvulus of the colon. Incidence and mortality. Ann Surg 1985;202:83–92.
[3] Ballantyne GH. Review of sigmoid volvulus: history and results of treatment. Dis Colon Rectum 1982;25:494–501.
[4] Gingold D, Murrell Z. Management of colonic volvulus. Clin Colon Rectal Surg 2012;25:236–44.
[5] Bagarani M, Conde AS, Longo R, Italiano A, Terenzi A, Venuto G. Sigmoid volvulus in West Africa: a prospective study on surgical treatments. Dis Colon Rectum 1993;36:186–90.
[6] Raveenthiran V, Madiba TE, Atamanalp SS, De U. Volvulus of the sigmoid colon. Colorectal Dis 2010;12:1–17.
[7] Gaagen van Leeuwen JH. Sigmoid volvulus in a West Africa population. Dis Colon Rectum 1985;28:712–6.
[8] Halabi WJ, Jafari MD, Kang CY, et al. Colonic volvulus in the United States. Trends, outcomes and predictors of mortality. Ann Surg 2014;259:293–301.
[9] Raveenthiran V. Emptiness of the left iliac fossa: a new clinical sign of sigmoid volvulus. J Postgrad Med 2004;50:27–9.
[10] Madiba TE, Haffajee MR. Sigmoid colon morphology in the population groups of Durban, South Africa, with special reference to sigmoid volvulus. Clin Anat 2011;24:441–53.
[11] Akinkuotu A, Samuel JC, Msiska N, Mvula C, Charles AG. The role of the anatomy of the sigmoid colon in developing sigmoid volvulus: a case-control study. Clin Anat 2011;24:634–7.
[12] Margolin DA, Whitlow CB. The pathogenesis and etiology of colonic volvulus. Semin Colon Rectal Surg 2007;18:79–86.
[13] Chung Y, Eu K, Nyam D, et al. Minimizing recurrence after sigmoid volvulus. Br J Surg 1999;86:231–3.
[14] Shepherd JJ. The epidemiology and clinical presentation of sigmoid volvulus. Br J Surg 1969;56:353–9.
[15] Frisancho D, Frisancho O, Chacon P. Retractil mesocolonitis: pathophysiology and complications. Rev Gastroenterol Peru 1998;18:114–8.
[16] Altarac S, Glavas M, Drazinic I, et al. Experimental and clinical study in the treatment of sigmoid volvulus. Acta Med Croatia 2001;55:67–71.
[17] Lubrano J, Paquette B, Delabrousse E, Koch S, Mantion G. Volvulus du sigmoïde. EMC Gastroenterol 2012;7:1–6.
[18] Hasbahceci M, Basak F, Alimoglu O. Cecal volvulus. Indian J Surg 2012;74:476–9.
[19] Tiah L, Goh SH. Sigmoid volvulus: diagnostic twists and turns. Eur J Emerg Med 2006;13:84–7.
[20] Shepherd JJ. Treatment of volvulus of sigmoid colon: a review of 425 cases. Br Med J 1968;1:280–3.
[21] Bruzzi M, Lefèbre JH, Desaint B, et al. Management of acute sigmoid volvulus: short and long-term results. Colorectal Dis 2015;17(10):922–8.
[22] Rogers RL, Harford FJ. Mobile cecum syndrome. Dis Colon Rectum 1984;27:399–402.
[23] Atamanalp SS. Treatment of sigmoid Volvulus: a single-center experience of 952 patients over 46.5 years. Tech Coloproctol 2013;17:561–9.
[24] Atamanalp SS, Ozturk G. Sigmoid volvulus in the elderly: outcomes of a 43-year, 454-patient experience. Surg Today 2011;41:514–9.
[25] Atamanalp SS, Kisaoglu A, Ozogul B. Factors affecting bowel gangrene development in patients with sigmoid volvulus. Ann Saudi Med 2013;33:144–8.
[26] Bhatnagar BNS, Sharma CLN, Gautam A, Kakar A, Reddy DCS. Gangrenous sigmoid volvulus: a clinical study of 76 patients. Int J Colorectal Dis 2004;19:134–42.
[27] Grossmann EM, Longo WE, Stratton MD, Virgo KS, Johnson FE. Sigmoid volvulus in department of veterans affairs medical centers. Dis Colon Rectum 2000;43:414–8.
[28] Kuzu MA, Aslar AK, Soran A, Polat A, Topcu O, Hengirmen S. Emergent resection for acute sigmoid volvulus: result of 106 consecutive cases. Dis Colon Rectum 2002;45:1085–90.
[29] Consorti ET, Liu TH. Diagnosis and treatment of caecal volvulus. Postgrad Med J 2005;81:772–6.
[30] Oren D, Atamanalp SS, Aydinli B, et al. An algorithm for the management of sigmoid colon volvulus and the safety of primary resection: experience with 827 cases. Dis Colon Rectum 2007;50:489–97.
[31] Turan M, Sen M, Karadayi A, et al. Our sigmoid colon volvulus experience and benefits of colonoscope in detortion process. Rev Esp Enferm Dig 2004;96:32–5.
[32] Larkin JO, Thekiso TB, Waldron R, Barry K, Eustace PW. Recurrent sigmoid volvulus-early resection may obviate later emergency surgery and reduce morbidity and mortality. Ann R Coll Surg Engl 2009;91:205–9.
[33] Mulas C, Bruna M, Garcia-Armengol J, Roig JV. Management of colonic volvulus. Experience in 75 patients. Rev Esp Enferm Dig 2010;102:239–48.
[34] Swenson BR, Kwaan MR, Burkart NE, et al. Colonic volvulus: presentation and management in metropolitan Minnesota, United States. Dis Colon Rectum 2012;55:444–9.
[35] Tan KK, Chong CS, Sim R. Management of acute sigmoid volvulus: an institution's experience over 9 years. World J Surg 2010;34:1943–8.
[36] Yassaie O, Thompson-Fawcett M, Rossaak J. Management of sigmoid volvulus: is early surgery justifiable? ANZ J Surg 2013;83:74–8.
[37] Hines JR, Geurkink RE, Bass RT. Recurrence and mortality rates in sigmoid volvulus. Surg Gynecol Obst 1967;124:567–70.
[38] Ifversen AKW, Kjaer DW. More patients should undergo surgery after sigmoid volvulus. World J Gastroenterol 2014;20:18384–9.
[39] Tsai MS, Lin MT, Chang KJ, Wang SM, Lee PH. Optimal interval from decompression to semi-elective operation in sigmoid volvulus. Hepatogastroenterology 2006;53:354–6.
[40] Baraza IR, Brown S, McAlindon M, Hurlstone P. Prospective analysis of percutaneous endoscopic colostomy at a tertiary referral centre. Br J Surg 2007;94:1415–20.
[41] Cowlam S, Watson C, Elltringham M, et al. Percutaneous endoscopic colostomy of the left side of the colon. Gastrointest Endosc 2007;65:1007–14.
[42] Daniels IR, Lamparelli MJ, Chave H, Simson JN. Recurrent sigmoid volvulus treated by percutaneous endoscopic colostomy. Br J Surg 2007;87:1419.
[43] Gordon-Weeks AN, Lorenzi B, Lim J, Cristaldi M. Laparoscopic assisted endoscopic sigmoidopexy: a new surgical option for sigmoid volvulus. Dis Colon Rectum 2011;54:645–7.
[44] Kasten K, Marcello P, Roberts P, et al. What are the results of colonic volvulus surgery. Dis Colon Rectum 2015;58:502–7.
[45] Burke JB, Ballantyne GH. Cecal volvulus. Low mortality at a city hospital. Dis Colon Rectum 1984;27:737–40.
[46] Inberg MV, Havia T, Davidsson L, Salo M. Acute intestinal volvulus. A report of 238 cases. Scand J Gastroenterol 1972;7:209–14.
[47] Anderson JR, Welch GH. Acute volvulus of the right colon: an analysis of 69 patients. World J Surg 1986;10:336–42.
[48] Alves A, Panis Y, Mantion G, Slim K, Kwiatkowski F, Vicaut E. The AFC score: validation of a 4-item predicting score of postoperative mortality after colorectal resection for cancer or diverticulitis: results of a prospective multicenter study in 1049 patients. Ann Surg 2007;246:91–6.
[49] Strom PR, Stone HH, Fabian TC. Colonic atony in association with sigmoid volvulus: its role in recurrence of obstructive symptoms. South Med J 1982;75:933–6.
[50] Booij K, Tanis PJ, van Gulik TM, Gouma DJ. Recurrent volvulus of the transverse colon after sigmoid resection. Int J Colorectal Dis 2009;24:471–2.
[51] Ryan P. Sigmoid volvulus with and without megacolon. Dis Colon Rectum 1982;25:673–9.
[52] Morissey T, Deitch E. Recurrence of sigmoid volvulus after surgical intervention. Am Surg 1994;60:329–31.
[53] Basato S, Lin Sun Fui S, Pautrat K, Tressalet C, Pocard M. Comparison of two surgical techniques for resection of uncomplicated sigmoid volvulus: Laparoscopy or open surgical approach? J Visc Surg 2014;151:444–8.

[54] Renzulli P, Maurer CA, Netzer P, Büchler MW. Preoperative colonoscopic derotation is beneficial in acute colonic volvulus. Dig Surg 2002;19:223–9.
[55] Alshawi JS. Recurrent sigmoid volvulus in pregnancy: report of a case and review of the literature. Dis Colon Rectum 2005;48:1811–3.
[56] Palmucci S, Lanza ML, Gulino F, Scilletta B, Ettorre GC. Diagnosis of sigmoid volvulus in pregnancy: ultrasonography and magnetic resonance imaging findings. J Radiol Case Rep 2014;8(2):54–62.
[57] Loke KL, Chan CS. Case report: transverse colon volvulus: unusual appearance on barium enema and review of the literature. Clin radiol 1995;50:342–4.
[58] Mandal A, Chandel V, Baig S. Ileosigmoid knot. Indian J Surg 2014;74:136–42.
[59] Kotisso B, Bekele A. Ilio-sigmoid knotting in Addis Ababa: a 3-year comprehensive retrospective analysis. Ethiop Med J 2006;44:377–83.

Colonic Atony in Association With Sigmoid Volvulus: Its Role in Recurrence of Obstructive Symptoms*

PRISCILLA R. STROM, MD, H. HARLAN STONE, MD, and TIMOTHY C. FABIAN, MD, Atlanta, Ga

ABSTRACT: We reviewed a 30-year experience in management of 129 patients with 163 acute obstructions due to sigmoid volvulus. Recurrent obstruction of the colon was observed in 47 (or 45%) of 104 patients who survived their initial obstructive episode: 61% after rectal tube insertion, 45% after detorsion, 33% after sigmoid plication, and 21% despite sigmoid colectomy. Subsequent barium enema or surgical exploration showed true sigmoid volvulus to be the cause of recurrent obstruction in 36 of 47 patients, while atonic bowel, involving the sigmoid alone or more proximal colon as well, was responsible for the other 11 recurrent obstructions. Sigmoid excision was corrective only if bowel atony was limited to that portion of the colon. Only more extensive colectomy, so as to include all flaccid colon, consistently obviated recurrence. Failure to recognize functional obstruction accounted for five of the 25 total deaths.

RECURRENT COLONIC OBSTRUCTION is relatively common in patients with a documented history of sigmoid volvulus. However, when the same symptoms occur after sigmoid colectomy, management becomes somewhat perplexing. Under such circumstances, seldom does any treatment modality provide long-term success unless it includes resection of all atonic bowel. Otherwise, persistence of this complete or partial functional obstruction leads to progressive inanition, often terminated by some lethal complication relatively specific for untreated intestinal obstruction.

From a 30-year experience (1951 to 1980) in the management of 129 patients with 163 acute episodes of colon obstruction related to sigmoid volvulus, we identified 11 instances of atony of the more proximal part of the colon. This frequency of 9% appeared to warrant further study and accordingly prompted the present review.

PATIENT MATERIAL

The 129 patients ranged in age from 5 to 99 years, with an average of 63.9 years. There were 98 blacks and 31 whites; 94 patients were male and 35, female.

Management for the final episode of obstruction and the corresponding mortality for each method are given in Table 1. Whenever tube decompression could be accomplished, such was attended by the lowest mortality, ie, 6%. When laparotomy was required, yet viable bowel was discovered, detorsion with or without sigmoidopexy carried a 22% fatality rate. With sigmoid colectomy, the mortality increased to 33%, being more than doubled by the need for an emergency resection (nine of 21 or 43% versus three of 15 or 20%).

Symptoms of sigmoid volvulus occurred in 47, or 45%, of the 104 survivors (Table 2). No method of prior management was immune to failure. Recurrence of volvulus-like obstruction was recorded in 60% after sigmoidoscopic tube decompression, in 41% after laparotomy with or without suture fixation of the bowel, and in 21% even after sigmoid colectomy.

The usual cause of recurrence was a second sigmoid volvulus in 36 of the 47 patients (Table 3). In 11 patients, however, barium enema and/or repeat laparotomy confirmed the absence of torted colon and revealed instead an adynamic proximal large bowel. Five of the 11 patients without recurrent volvulus had previously had sigmoid colectomy.

In four patients, the entire colon was dilated, patulous, and functionless. In two, only the ascending colon appeared to be normal, while in the remaining five the

TABLE 1. Management of Sigmoid Volvulus

Method	*No.*	*Died*	*Mortality*
Sigmoidoscopy with tube decompression	51	3	6%
Laparotomy with detorsion only	27	7	26%
Laparotomy with sigmoidopexy	14	2	14%
Laparotomy with sigmoidectomy	36	12	33%
Discovered at necropsy	1	1	100%
Total	129	25	19%

*Read before the Section on Surgery, Southern Medical Association, 75th Annual Scientific Assembly, New Orleans, La, Nov 15-18, 1981.

From the Department of Surgery, Emory University School of Medicine, Atlanta, Ga.
Reprint requests to H. Harlan Stone, MD, Department of Surgery, Emory University, 69 Butler St SE, Atlanta, GA 30303.

TABLE 2. Management and Recurrence of Volvulus-like Symptoms

Method	No.	"Recurrence"	Incidence
Sigmoidoscopy with tube decompression	48	29	60%
Laparotomy with detorsion only	20	9	45%
Laparotomy with sigmoidopexy	12	4	33%
Laparotomy with sigmoidectomy	24	5	21%
Total	104	47	45%

adynamic segment included the descending as well as the sigmoid colon.

Failure to appreciate colonic atony as the cause of persisting or recurring obstruction accounted for five (20%) of the 25 deaths (Table 4). Two patients languished and eventually died as a result of uncorrected colonic obstruction when bowel atony was the only identifiable explanation for their condition. In two other deaths, laparotomy with detorsion in one and both detorsion and sigmoidopexy in the other did not relieve the functional obstruction. Despite a "mechanically open" colon, as shown by barium enema, both patients died of complications of unrelieved obstruction of the large bowel. The final death, due in part to an adynamic colon, was recorded in a patient whose volvulus had been relieved by tube decompression, yet in whom normal bowel function never returned despite the free flow of barium into and out of the sigmoid colon.

Six patients with colonic atony were identified before discharge from the hospital by failure of the more proximal segment to empty on barium enema examination. The 24-hour postevacuation film consistently showed a functional obstruction in each of these cases. Accordingly, colectomy was done with resection of all obviously atonic bowel. In one patient, this even required a total abdominal colectomy with reanastomosis by ileoproctostomy. There were no episodes of recurrent obstruction in any patient who had excision of such delineated adynamic colon.

In the 11 patients with colonic atony, the completeness of functional obstruction appeared related to length of bowel involved. If only the sigmoid colon was flaccid, the obstruction was always partial. However, when the entire left colon was massively dilated and failed to empty, the resultant functional obstruction was essentially complete. Despite resection of

TABLE 3. Cause of Recurrent Volvulus-like Symptoms

Method of Management	No. "Recurred"	Sigmoid Volvulus	Colonic Atony
Tube decompression	29	28	1
Detorsion only	9	7	2
Sigmoidopexy	4	1	3
Sigmoidectomy	5	–	5
Total	47	36	11

TABLE 4. Persisting Obstructive Symptoms Due to Colonic Atony as an Underlying Cause of Death

Method of Management	Died	Colonic Atony
Tube decompression	8	1
Detorsion only	7	1
Sigmoidopexy	2	1
Sigmoidectomy	12	2
Necropsy	1	–
Total	25	5

adynamic sigmoid colon, atony of the residual large bowel was equally obstructive (Figs 1, 2, and 3).

DISCUSSION

Chronic constipation is a common malady that can have various causes.[1-4] Hirschsprung's disease, collagen vascular disorders, neuromuscular degenerative processes, and various drugs have all been implicated. Such are typically found in elderly and in bedridden patients, though laxative abuse has also been incriminated. The large, dilated, and redundant colon seen in this patient population comprises a subgroup of megacolon disorders. The underlying cause of the megacolon and constipation in these patients is unknown, and it has not been demonstrated which comes first—megacolon or constipation. If, however, motility of the large bowel is examined by barium enema, effective peristalsis is found to be almost nonexistent in the dilated bowel. Whether absence of motility first pro-

FIGURE 1. Dilated residual colon after sigmoid colectomy.

FIGURE 2. Barium enema showing absence of sigmoid colon and free flow of contrast material.

FIGURE 3. Postevacuation film, taken at 24 hours, showing large amount of retained barium.

duces constipation and megacolon or whether it is chronic constipation that precedes dilatation and subsequent loss of motor tone is uncertain and probably moot. The practical problem to be faced is that a colon with absent or ineffective peristalsis often produces a functional obstruction, which may indeed become complete.

Discussions of this problem in the surgical literature usually detail reports of intestinal pseudo-obstruction and encompass hypomotility disorders for all parts of the gastrointestinal tract.[1-4] Many of these cases are also hidden in reports of sigmoid volvulus. Most papers directed toward the surgical management of sigmoid volvulus focus on the controversy over resection as opposed to other methods with respect to the incidence of recurrence after each type of treatment.[5,6] However, from these reports can be culled specific cases of "recurrence of volvulus" or at least recurrent nonmechanical obstruction of the large bowel after complete resection of the sigmoid colon.[7-13] Including our series, 20 such cases have been documented in the surgical literature (Table 5). It appears that the recurrence rate for such functional obstruction is approximately 10%, provided that more proximal adynamic bowel has not been excised.

TABLE 5. Previous Reports of "Recurrent Volvulus" After Sigmoid Colectomy

Year	*Authors*	*Patients Having Resection*	*Recurrent Symptoms*	*Incidence of "Recurrence"*
1968	Shepherd[12]	310	2	0.6%
1968	Sutcliffe[13]	22	1	5%
1969	Ponka[10]	6	1	17%
1976	Nemur et al[9]	15	1	7%
1976	Moseson et al[8]	22	3	14%
1976	Sharpton & Cheek[11]	50	5	10%
1979	Harbrecht & Fry[7]	—	2	—
	Present series	24*	5	21%

*24 survivors at risk for recurrence out of 36 who had sigmoid colectomy.

Experience suggests that patients with sigmoid volvulus due to colonic atony are only a subset of a larger group with various lengths of redundant and hypotonic colon. If the patient with sigmoid volvulus has sigmoid resection only, whether at emergency exploration or as a later elective procedure, there is a 10% incidence of recurrent obstructive symptoms. This appears to be caused by a functional obstruction created by a retained atonic colon with poor or absent peristalsis. It is often difficult initially to distinguish whether the distal obstruction is due to sigmoid volvulus or instead to a chronic adynamic state. The differentiation requires decompression of the bowel with a rectal tube so as to eliminate the threat of progression to gangrene, followed by a barium enema after four or five days of sigmoid deflation. Such a time interval

allows the colon to recover from the acute effects of obstruction and thereby to regain its normal motor tone. Under fluoroscopy, the radiologist should look carefully for signs of effective peristalsis and, in particular, should notice the distal limit of such activity. Delay of the follow-up abdominal films for 12 to 24 hours after completion of the contrast study will then show any failure of barium to be completely evacuated, a clear indication of ineffective peristalsis. Such observations can determine whether the patient has an atonic colon and, if so, what length of colon is involved. When elective surgery is done, all abnormal large bowel must be resected, regardless of whether confined to the sigmoid colon alone or to more proximal segments, often including the entire colon. Only through adequate resection can the possibility of recurrent postoperative obstruction be avoided.

Although such an approach advocates what may be considered relatively extensive surgery in an elderly population, segmental colectomy or even total colectomy is well tolerated as long as the patient is a reasonably good surgical risk. There is no doubt that operation is the only choice for those patients who suffer frequent recurrences of functional obstruction and thus repeated hospital admissions. As long as a portion of the ascending colon is retained, resection of the remainder of the large bowel seldom leads to troublesome diarrhea. Indeed, two or three soft stools each day are often considered a blessing for patients long plagued by refractory constipation.

References

1. Golladay ES, Byrne WJ: Intestinal pseudo-obstruction. *Surg Gynecol Obstet* 153:257-273, 1981
2. Lane HS, Todd IP: Idiopathic megacolon: a review of 42 cases. *Br J Surg* 64:305-310, 1977
3. Mahorner H: Surgery for intractable constipation. *Am Surg* 36:119-123, 1970
4. Schuffler MD, Deitch EA: Chronic idiopathic intestinal pseudo-obstruction: a surgical approach. *Ann Surg* 192:752-761, 1980
5. Arnold GJ, Nance FC: Volvulus of the sigmoid colon. *Ann Surg* 177:527-537, 1973
6. Drapanas T, Stewart JD: Acute sigmoid volvulus: concepts in surgical treatment. *Am J Surg* 101:70-77, 1961
7. Harbrecht PJ, Fry DE: Recurrence of volvulus after sigmoidectomy. *Dis Colon Rectum* 22:420-424, 1979
8. Moseson DL, Lindell T, Brant B, et al: Sigmoid volvulus. *Am Surg* 42:492-497, 1976
9. Nemur FD, Hagihara PF, Mays ET, et al: Volvulus of the colon—a continuing surgical problem. *Dis Colon Rectum* 19:321-329, 1976
10. Ponka JL: Volvulus of the colon. *Dis Colon Rectum* 12:430-437, 1969
11. Sharpton B, Cheek RC: Volvulus of the sigmoid colon. *Am Surg* 42:436-440, 1976
12. Shepherd JJ: Treatment of volvulus of sigmoid colon: a review of 425 cases. *Br Med J* 1:280-283, 1968
13. Sutcliffe MML: Volvulus of the sigmoid colon. *Br J Surg* 55:903-910, 1968

CERTIFICATE OF FILING AND SERVICE

I certify that on the 26th day of January, 2018, I filed the original **BRIEF OF RESPONDENTS** with the Court of Appeals, Division II by Electronic Filing.

I further certify that on the same date, I caused the foregoing to be served upon the following counsel of record by electronic filing:

Ken W. Masters
Masters Law Group, PLLC
241 Madison Avenue North
Bainbridge Island, WA 98110
ken@appeal-law.com

Stephen Hornbuckle
The Hornbuckle Firm
1408 140th Place NE, Suite 250
Bellevue, WA 98007
shornbuckle@thehornbucklefirm.com

Respectfully Submitted this 26th day of January, 2018.

HART WAGNER LLP

By: */s/ Matthew J. Kalmanson*
Matthew J. Kalmanson, WSB No. 41262
Of Attorneys for Respondents

HART WAGNER LLP

January 26, 2018 - 2:27 PM

Transmittal Information

Filed with Court:	Court of Appeals Division II
Appellate Court Case Number:	50336-1
Appellate Court Case Title:	Geraldine Iverson, P.R. for Estate of Bessie Ritter v Prestige Care, Inc., et al, Respondents
Superior Court Case Number:	15-2-00391-5

The following documents have been uploaded:

- 503361_Briefs_20180126142643D2829795_2272.pdf
  This File Contains:
  Briefs - Respondents Reply
  The Original File Name was Brief of Respondents.pdf

A copy of the uploaded files will be sent to:

- frh@hartwagner.com
- ken@appeal-law.com
- paralegal@appeal-law.com
- shornbuckle@thehornbucklefirm.com

Comments:

Sender Name: Florence Hoblitzell - Email: frh@hartwagner.com
Filing on Behalf of: Matthew J Kalmanson - Email: MJK@hartwagner.com (Alternate Email:)

Address:
1000 SW Broadway
20th Floor
Portland, OR, 97205
Phone: (503) 222-4499

Note: The Filing Id is 20180126142643D2829795